© 2010 John Wiley & Sons A/S

Transplant Infectious Disease . ISSN 1398-2273

Case report

Donor-transmitted adenovirus infection causing kidney allograft nephritis and graft loss

T. Kozlowski, V. Nickeleit, K. Andreoni. Donor-transmitted adenovirus infection causing kidney allograft nephritis and graft loss. Transpl Infect Dis 2011: **13**: 168–173. All rights reserved

Abstract: Adenovirus (AdV) infection can occur early after transplantation, especially with potent immunosuppression for induction or acute rejection treatment. We present the largest case series of adult renal recipients from a single institution with AdV infection, and the first apparent case of transferred AdV infection from 1 deceased donor to 2 kidney recipients. Three patients received kidneys from 2 deceased donors: 2 from a 23-year-old donor, and the third from a 4-year-old donor. The recipients with the same donor both displayed early rejection. One who eventually lost his graft to AdV nephritis required treatment with plasmapheresis, intravenous immunoglobulin, rituximab, and anti-thymocyte globulin for severe antibody-mediated rejection. The second required only steroids for acute cellular rejection and has good renal function at 7 years. The third recipient was discovered to have AdV and microabscesess on renal biopsy and required nephrectomy. In the 2 cases of graft loss, we observed sudden deterioration of graft function with rising creatinine and subsequent necrosis resulting in nephrectomy within 40 days after transplantation. AdV was detected by polymerase chain reaction in urine or serum and/or renal tissue. AdV activation after potent immunosuppression can lead to systemic infection and may trigger rejection and/or early graft loss.

T. Kozlowski[1], V. Nickeleit[2], K. Andreoni[1,3]

[1]Department of Surgery, [2]Department of Pathology, University of North Carolina at Chapel Hill, Chapel Hill, North Carolina, USA, [3]Department of Surgery, The Ohio State University, Columbus, Ohio, USA

Key words: adenovirus; kidney transplant; transmitted infection; immunosuppression

Correspondence to:
Tomasz Kozlowski, MD, Department of Surgery, University of North Carolina at Chapel Hill, 4023 Burnett-Womack Bldg, CB #7211, Chapel Hill, NC 27599 USA
Tel: +1 919 966 8008
Fax: +1 919 966 6308
E-mail: tomasz_kozlowski@med.unc.edu

Received 30 June 2010, revised 13 July 2010, accepted for publication 22 July 2010

DOI: 10.1111/j.1399-3062.2010.00572.x
Transpl Infect Dis 2011: **13:** 168–173

As more efficacious immunosuppressive agents allow for transplantation of immunologically high-risk patients, reactivation of latent viruses can be expected. Cytomegalovirus is the most common agent in this category. The rapid reemergence of BK or polyoma virus has brought this virus to the forefront of transplant physicians' concerns. Adenovirus (AdV) is another old nemesis, more often diagnosed in the pediatric population, but reemerging in adult solid organ transplant (SOT) recipients receiving potent immunosuppressive regimens, especially lymphocyte-depleting induction agents (1–3).

AdVs are nonenveloped double-stranded DNA viruses with a tropism for epithelial cells via coxsackievirus and AdV receptors, class I human leukocyte antigen molecules, and sialoglycoprotein receptors (3). Organ systems affected include the respiratory, gastrointestinal, and genitourinary systems. AdV infections are usually self-limited in immunocompetent individuals, but the virus usually takes a latent form in the host. Immunocompromised hosts can develop systemic infections, organ dysfunction, and, occasionally, death from this viral infection. AdV can reactivate from a latent form in the host, as well as be transmitted by a donor graft. In SOT recipients, AdV often attacks the transplanted organ (1, 3).

Among abdominal organ recipients, small bowel recipients are most frequently diagnosed with AdV illness. This may be due to the lymphatic mass that is transplanted with the intestinal graft, serving as a reservoir of potential virus (4). Pediatric liver recipients are also commonly reported with AdV infection, including hepatitis, colitis, and pneumonitis. Kidney recipients have been sporadically reported with AdV infection, usually discovered after renal biopsy for elevated serum creatinine (3). A recent surveillance study of AdV in the serum of adult SOT recipients demonstrated that 8.3% were AdV positive by polymerase chain reaction (PCR) after liver transplantation, 6.5% after kidney transplantation, and 6.7% after heart transplantation (5). AdV may be isolated in up to 20% of pediatric bone marrow recipients, with death in about 6% of symptomatic patients (6).

Treatment for AdV is primarily reduction of immunosuppression in transplant recipients. For patients who do not

improve through reduction of immunosuppression alone, treatment may consist of passive immunity through pooled intravenous immunoglobulin (IVIg), or the antiviral agents ribavirin, cidofovir, or valganciclovir (2, 7–10).

Case reports

Patient 1 (P1) and Patient 2 (P2) with Donor (D1)

D1

A 23-year-old male suffered a fatal intercerebral injury due to a motor vehicle crash 72 h before donation. He had no significant medical history and serologies were positive for cytomegalovirus IgG and hepatitis B surface antibody from vaccination. The donor received several blood transfusions.

P1

P1 was a 44-year-old African American male with historic T-cell panel reactive antibodies (PRA) of 98%, but a current PRA of 0%, no prior transplant, 20-year history of hypertension, and was on hemodialysis for 10 years. He had an upper respiratory infection 2 weeks previously, with a very mild residual dry cough. He was afebrile, chest x-ray was clear, with a normal serum white blood cell count. P1 had a negative T-cell anti-human globulin-augmented complement-dependent cytotoxicity (AHG-CDC) crossmatch and CDC B-cell crossmatch on the day of transplantation.

P1 received induction with 3 doses (total 5 mg/kg) of rabbit anti-thymocyte globulin (ATG) (Thymoglobulin®, Genzyme, Cambridge, Massachusetts, USA) and maintenance tacrolimus, mycophenolate mofetil (MMF), and prednisone. He received prophylactic therapy with valganciclovir 450 mg a day and trimethoprim/sulfamethoxazole once every other day. P1 had good renal graft function over the first 2 days post transplantation. He had good urine output and a creatinine decrease from 10.6 to 3.1 mg/dL on postoperative day (POD) 5.

On POD 6, P1 had a sudden decrease in urine output with a creatinine increase to 4.2 mg/dL. Tacrolimus trough level was 10 ng/mL. His absolute lymphocyte count was 0.1 cells/nL. With the presumed diagnosis of antibody-mediated rejection, donor-specific antibody (DSA) titers were drawn and he was given methylprednisolone pending biopsy. A renal biopsy on POD 7 revealed pure antibody-mediated rejection with prominence and dilatation of the peritubular capillaries containing mononuclear cells and neutrophils. C4d staining was strongly positive along the peritubular capillaries. Viral cytopathic changes were not seen within the tubules, and the arterioles and small arteries were normal. Repeat T-cell AHG-CDC crossmatch against cryopreserved donor cells, as well as surrogate donor cells, was now positive (1:8). T-PRA increased from 0% pre-transplant to 45% on POD 6.

The patient was given rituximab 375 mg/m^2 the night of biopsy and then started on plasmapheresis for 10 treatments. The patient's absolute lymphocyte count was low from ATG induction. He also received intermittent doses of IVIg to prevent rebound of DSA. DSA was defined against B81, and surrogate donor cells were used to follow DSA over the course of plasmapheresis. P1 demonstrated progressive decrease in positive AHG-CDC titer against surrogate cells: POD 7 1:8; POD 12 1:4, and POD 14 1:2. P1's urine output improved significantly toward the end of his plasmapheresis treatments and his creatinine decreased to 3.5 mg/dL. He had 5 days of excellent urine output before his urine output again trended downward and creatinine increased.

Five days later, the patient developed a sore throat and high fever with generalized malaise and rigors. A chest x-ray showed a left lower lobe infiltrate. Initial Gram stain and early culture obtained from bronchoalveolar lavage (BAL) were negative. His exam and constitutional signs worsened, and he developed gross hematuria with tenderness and pain to palpation over the renal graft. The graft was removed urgently on POD 24.

Approximately 50% of the kidney was histologically normal without signs of cellular or humoral rejection, but the remainder demonstrated dilated tubules as a sign of acute injury, and focal vacuolization of the cytoplasm. In several areas of the renal cortex, a necrotizing tubulointerstitial nephritis rich in polymorphonuclear leukocytes was identified, secondary to an AdV infection with characteristic intranuclear viral inclusion bodies in tubular epithelial cells. In the inflamed areas, small foci of hemorrhage were also identified. The necrotizing tubulo-interstitial nephritis accounted for approximately 30% of the parenchyma. Intranuclear viral inclusion bodies were noted adjacent to the severely inflamed and destroyed regions in intact tubular cross sections. There was no transplant endarteritis. The renal collecting system epithelium did not reveal any intranuclear viral inclusion bodies.

Immunosuppression was rapidly tapered. The patient was treated with valganciclovir for another month. P1 was discharged home 4 days later and had viral syndrome symptoms for 2 more weeks. The BAL culture returned positive for AdV 6 days after discharge. He was seen in clinic 1 month later and was completely recovered. Electron microscopy, immunofluorescence staining, and PCR evaluation of the nephrectomy tissue confirmed AdV.

P1 AdV testing

Baseline renal graft biopsy at the time of transplantation was negative for AdV by PCR. Also negative for AdV by PCR were P1's renal graft biopsy on POD 9 and serum samples pre-transplant and early post nephrectomy.

Immunohistochemistry and PCR testing for AdV were positive on P1's nephrectomy specimen. This tissue was sent to the Adenoviral Consortium, University of Iowa, for typing and returned Ad34. P1's BAL culture was positive for AdV by cell culture and immunofluorescence testing.

P2

P2 was a 56-year-old African American male with renal failure due to glomerulonephritis, who was on hemodialysis for 6 years. He had type II diabetes, hypertension, hypercholesterolemia, and gout. He presented in stable condition, with a benign exam and clear chest x-ray. His PRA was 0%. P2 had a negative T-cell AHG-CDC crossmatch and CDC B-cell crossmatch on the day of transplantation.

P2 also received our standard induction with 3 doses of ATG (total 5 mg/kg) and maintenance tacrolimus, MMF, and prednisone. He also received prophylactic therapy with valganciclovir 450 mg a day and trimethoprim/sulfamethoxazole once every other day. P2 had early renal graft function and was discharged on POD 7 with a creatinine of 2.8 mg/dL from 13.0 mg/dL before surgery. His creatinine stabilized at 2 mg/dL. An implantation, reperfusion renal graft biopsy demonstrated no intrinsic abnormalities with mild acute tubular necrosis.

On POD 19, after being home for 2 weeks, P2 had fever and dysuria. Upon admission, he had wheezing and fevers. At discharge 14 days later, cultures obtained from BAL, blood, and urine were negative for bacteria, fungi, and viruses. Twelve days after discharge, the urine returned positive for AdV. In response, the patient's MMF was decreased from 1 g twice a day (b.i.d.) to 500 mg b.i.d. and valganciclovir was increased to 900 mg b.i.d. for 3 months, then tapered to 450 mg once a day for another 6 weeks.

The patient's creatinine increased from 2.0 to 2.6 mg/dL at the time the AdV urine result returned. This prompted a biopsy at 7 weeks post transplant to evaluate for rejection versus viral injury. The biopsy showed Banff 1B acute cellular rejection with severe tubulitis and negative C4d staining. The patient responded to a short steroid pulse and his creatinine declined to his baseline range of 1.7–2.0 mg/dL within 5 days. A follow-up biopsy 1 month later revealed no rejection or viral cytopathic effect. P2 had several repeat urine cultures that were negative for AdV and he has a serum creatinine of 1.5–1.6 mg/dL at 7 years of follow-up.

P2 AdV testing

AdV typing was attempted on P2's positive AdV urine culture collected on POD 19. The virus did not type positive for serotypes 1 through 11 or 19 through 24 (Focus Technologies Inc., Cypress, California, USA).

Patient 3 (P3) with Donor (D2)

D2

D2 was a 4-year-old who died from severe burn injury with a prolonged stay in the intensive care unit.

P3

P3 was a 52-year-old African American, unsensitized, with renal failure due to focal segmental glomerulosclerosis and on chronic warfarin therapy for an aortic valve replacement, who received a pediatric graft from D2. P3 had a negative AHG-CDC T-cell and CDC B-cell crossmatch. He received 30 mg of alemtuzumab induction with tacrolimus, MMF, and prednisone. Because of prolonged delayed graft function (DGF), prednisone was not stopped, but was decreased to 10 mg by POD 5 and then to 5 mg at 1 month. His course was complicated by DGF and a perirenal hematoma due to rapid systemic anticoagulation to protect the patient's mechanical aortic valve. The patient required outpatient hemodialysis on an as-needed basis. P3 received open protocol biopsies on POD 8 and 20 because of his slowly resolving DGF and anticoagulation. These revealed only acute tubular necrosis with no signs of rejection or viral injury. The patient's creatinine was on a slow downward trend off hemodialysis, when it suddenly increased from 4.1 to 5.3 mg/dL.

The biopsy on POD 43 was interpreted as areas of necrosis with microabscesses, prompting an urgent graft nephrectomy in this patient with a mechanical heart valve (Figs. 1 and 2). The nephrectomy pathology showed a focal inflammatory pattern with areas of infarction suggestive of AdV infection, with no rejection. There was at least 15% gross infarction due to AdV and the graft was PCR positive for AdV. The patient recovered after nephrectomy and was restarted on hemodialysis.

P3 AdV typing

P3's serum from the day before nephrectomy was serotyped Ad2, while the nephrectomy specimen returned Ad6. A serum from the day of transplant was negative. Serum 5 days after nephrectomy remained AdV positive, but returned negative 2 and 6 weeks later. All samples from P3 were serotyped at the same time by the Adenoviral Consortium.

Discussion

These case presentations include the first case we could find in the literature demonstrating the likely transmission of AdV to 2 recipients of renal grafts from the same donor. Although we could not definitively subtype the AdV from

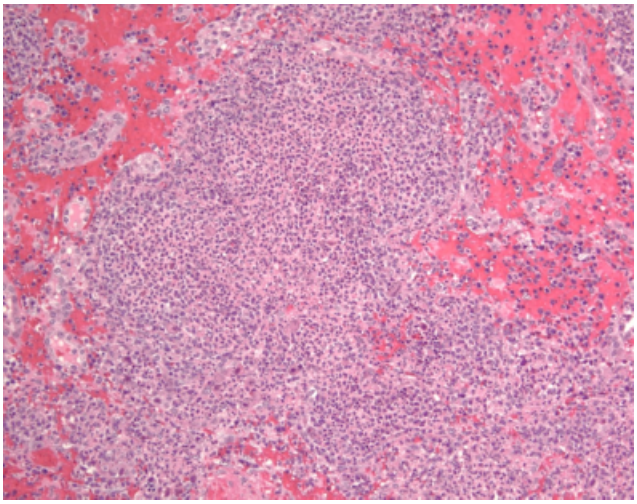

Fig. 1. Patient 3. Kidney allograft biopsy on postoperative day 43, day of graft nephrectomy. Nephritis and kidney parenchyma destruction with erythrocyte extravasation. The adjacent cortical and medullary zones revealed small areas of inflammation, mononuclear cell elements, as well as polymorphonuclear leukocytes, with focal segmental destruction of the tubular epithelial cell layer. In these areas only, scattered rare atypical epithelial cell nuclei were found. The tubular compartment demonstrated diffuse signs of injury with dilatation. Hemorrhage was only found in areas of frank necrosis. Immunohistochemical staining performed on formalin-fixed and paraffin-embedded tissue sections to detect SV40 ('pan polyoma virus antigen') as well as the immediate early cytomegalovirus antigen was negative. The glomeruli did not reveal any diagnostic accumulation of immunoglobulin (Ig)G, IgA, IgM, complement factor C3, complement factor C1q, or κ and λ light chains. The complement degradation product C4d was not detected along peritubular capillaries (hematoxylin and eosin staining, magnification × 10).

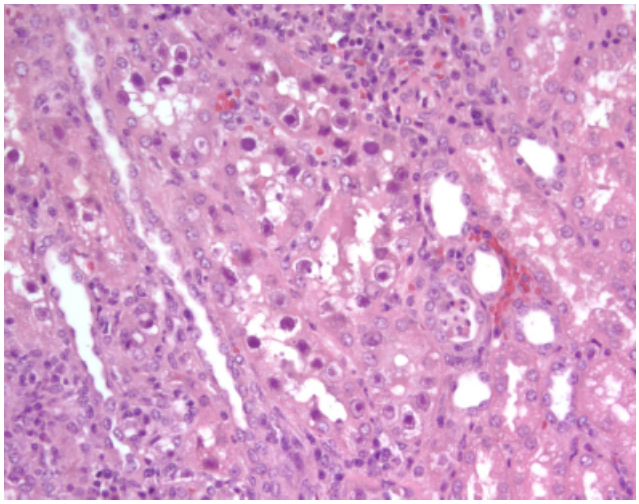

Fig. 2. Patient 3. Intranuclear inclusions. Very rare nuclei (presumably tubular epithelial cells) were enlarged with a smudgy appearance, suggestive of an adenovirus infection (hematoxylin and eosin staining, magnification × 20). Gram stain, acid-fast bacilli (Ziehl–Neelsen incubation), as well as fungal organisms (GMS incubation) (not shown) did not reveal any infectious agents.

P2's urine, as it was inadvertently discarded, the negative results (Ad 1–11 and 19–24) we did obtain are consistent with the Ad34 found in P1. The onset of P1's AdV infection on POD 24 did not allow for AdV testing in various tissues from the donor (D1). We do know that a renal biopsy at the time of transplant was negative by PCR analysis. The relatively early onset of the AdV infections in both of the recipients (POD 24 in P1's renal graft and POD 19 in P2's urine culture) from the same donor, and the recipients' ages of 44 and 56 years, argue against both recipients developing spontaneous AdV infections independent of the donor graft.

Both recipients received anti-lymphocyte induction therapy with ATG. The total dose employed of 5 mg/kg is common in immunologically higher risk recipients and in high-risk organ situations, such as DGF, and in rapid steroid discontinuation protocols (11–13). Despite anti-lymphocyte induction, both recipients had early rejection episodes while on tacrolimus, MMF, and prednisone maintenance therapy with good initial graft function. We may speculate that the presence of AdV in the graft tissue triggered rejection as has been described in cardiac transplantation (14). P1's high alloantibody level before transplantation is likely responsible for the difference in intensity of his rejection episode from P2, who was immunologically naïve.

The third patient received alemtuzumab induction that is more effective in T-cell depletion than a short course of ATG (15). He did not require treatment for acute rejection. His AdV infection was detected while he was asymptomatic because of protocol renal biopsies for resolving DGF.

The 23-year-old donor (D1) likely transmitted Ad34, a serotype associated with renal tropism in the immunocompromised host (16, 17). The 4-year-old donor (D2) appears to have transmitted Ad2 and 6 to the recipient. Both are common in the pediatric age group, with Ad2 seen in infant gastroenteritis. Ad2 and 6 are uncommon in transplant recipients and the young age of the donor is likely the reason for this unusual transmission.

These cases were the only clinically apparent AdV infections in adult transplant patients at our institution over several decades, and the first to result in graft dysfunction or loss. Antiviral drugs are not believed to be very effective against AdV, limiting treatment options to reduced immunosuppression and possibly passive immune enhancement with IVIg. The profound immunosuppression of multiple courses of plasmapheresis after ATG induction and maintenance triple immunosuppression therapy prevented P1's immune system from controlling this usually

harmless virus. The use of an infected donor graft along with alemtuzumab induction and triple therapy immunosuppression may explain the increased susceptibility of P3 to his AdV challenge.

Concerning to us was the inability of serum PCR testing to reliably demonstrate circulating AdV from serum of clearly infected patients, including days surrounding graft nephrectomy (P1). This was intriguing, considering P1 had a BAL culture obtained 48 h before nephrectomy that was eventually positive. The epithelial tropism of AdV may require nonserum samples for better sensitivity (4, 6, 18). An alternative explanation may be found in a review of the literature concerning AdV infection and detection. Detection of AdV from nonblood sites such as stool, urine, and nose/throat swabs tends to poorly correlate with severe disease unless the virus is isolated from multiple sites (6). Two investigators have shown that bone marrow transplant recipients may have only nonblood positive sites with a range of clinical findings from asymptomatic to moderate disease such as hemorrhagic cystitis or enteritis (19, 20). Both studies show that when serum contains high levels of detectable AdV by PCR, mortality is high. McLaughlin et al.'s investigation (4) notes only 1 pediatric SOT recipient with a positive blood PCR. This patient was a liver recipient with AdV hepatitis. Another patient in that report had an AdV infection by immunostaining of a lung biopsy, but negative blood and intestinal graft biopsy by PCR analysis. These findings led the author to conclude that culture of appropriate specimens, evaluation of histology, and PCR techniques should all be routinely used. Our patient, who was serum PCR positive around the time of his nephrectomy (P3), was asymptomatic and recovered quickly. His infection with pediatric strains Ad2 and 6 may explain this. The fact that he was subtyped with Ad2 from his serum and Ad6 from his graft is unexplainable to us. The subtyping methodology is molecularly based and the Iowa Adenoviral Consortium is highly confident of their results. Clearly, the 4-year-old donor (D2) who succumbed to severe burn injury was at high risk for viral reactivation.

The rapid appearance of AdV a few weeks after a renal biopsy with no histological or PCR evidence of AdV in 2 different patients (P1 and P3) emphasizes the swift rate at which AdV can reactivate and overtake an allograft.

Others have recently described PCR testing to detect low levels of AdV in asymptomatic SOT or bone marrow transplant recipients (4, 21, 22). This strategy may allow for early decrease in immunosuppression and reduced morbidity and mortality. The detection of AdV by PCR in serum from asymptomatic liver, heart, and kidney recipients in a recent surveillance study did not correlate with clinical events (5). McLaughlin et al. (4) acknowledge that intestinal biopsies may be positive by PCR testing owing to latent virus and may require culture of specimens in asymptomatic patients. Humar et al. (23) found low-level AdV viremia in lung recipients that was common and of no clinical consequence. To add to the present state of uncertainty, the detection of AdV in pediatric cardiac allograft recipients may correlate with both increased risk of rejection and graft loss (14).

The transplant community should pay close attention to these viral diseases in the latest trend of potent induction therapy with steroid-free maintenance immunosuppression. Viral nephritis should be considered in recipients with unexplained rise in creatinine after lymphocyte-depletion therapy.

References

1. Emovon OE, Chavin J, Rogers K, Self S. Adenovirus in kidney transplantation: an emerging pathogen? Transplantation 2004; 77 (9): 1474–1475.
2. Carter BA, Karpen SJ, Quiros-Tejeira RE, et al. Intravenous cidofovir therapy for disseminated adenovirus in a pediatric liver transplant recipient. Transplantation 2002; 74 (7): 1050–1052.
3. Kim SS, Hicks J, Goldstein SL. Adenovirus pyelonephritis in a pediatric renal transplant patient. Pediatr Nephrol 2003; 18 (5): 457–461.
4. McLaughlin GE, Delis S, Kashimawo L, et al. Adenovirus infection in pediatric liver and intestinal transplant recipients: utility of DNA detection by PCR. Am J Transplant 2003; 3 (2): 224–228.
5. Humar A, Kumar D, Mazzulli T, et al. A surveillance study of adenovirus infection in adult solid organ transplant recipients. Am J Transplant 2005; 5 (10): 2555–2559.
6. Baldwin A, Kingman H, Darville M, et al. Outcome and clinical course of 100 patients with adenovirus infection following bone marrow transplantation. Bone Marrow Transplant 2000; 26 (12): 1333–1338.
7. Hensley JL, Sifri CD, Cathro HP, et al. Adenoviral graft-nephritis: case report and review of the literature. Transpl Int 2009; 22 (6): 672–677.
8. Hatakeyama N, Suzuki N, Kudoh T, Hori T, Mizue N, Tsutsumi H. Successful cidofovir treatment of adenovirus-associated hemorrhagic cystitis and renal dysfunction after allogenic bone marrow transplant. Pediatr Infect Dis J 2003; 22 (10): 928–929.
9. Emovon OE, Lin A, Howell DN, et al. Refractory adenovirus infection after simultaneous kidney–pancreas transplantation: successful treatment with intravenous ribavirin and pooled human intravenous immunoglobulin. Nephrol Dial Transplant 2003; 18 (11): 2436–2438.
10. Arav-Boger R, Echavarria M, Forman M, Charache P, Persaud D. Clearance of adenoviral hepatitis with ribavirin therapy in a pediatric liver transplant recipient. Pediatr Infect Dis J 2000; 19 (11): 1097–1100.
11. Agha IA, Rueda J, Alvarez A, et al. Short course induction immunosuppression with thymoglobulin for renal transplant recipients. Transplantation 2002; 73 (3): 473–475.
12. Matas AJ, Ramcharan T, Paraskevas S, et al. Rapid discontinuation of steroids in living donor kidney transplantation: a pilot study. Am J Transplant 2001; 1 (3): 278–283.
13. Peddi VR, Bryant M, Roy-Chaudhury P, Woodle ES, First MR. Safety, efficacy, and cost analysis of thymoglobulin induction therapy with intermittent dosing based on CD3 + lymphocyte counts in kidney and kidney–pancreas transplant recipients. Transplantation 2002; 73 (9): 1514–1518.
14. Shirali GS, Ni J, Chinnock RE, Johnston JK, et al. Association of viral genome with graft loss in children after cardiac transplantation. N Engl J Med 2001; 344 (20): 1498–1503.

15. Ciancio G, Burke GW 3rd. Alemtuzumab (Campath-1H) in kidney transplantation. Am J Transplant 2008; 8 (1): 15–20.
16. Hierholzer JC. Adenoviruses in the immunocompromised host. Clin Microbiol Rev 1992; 5 (3): 262–274.
17. Rosario RF, Kimbrough RC, Van Buren DH, Laski ME. Fatal adenovirus serotype-5 in a deceased-donor renal transplant recipient. Transpl Infect Dis 2006; 8 (1): 54–57.
18. Echavarria M, Forman M, Ticehurst J, Dumler JS, Charache P. PCR method for detection of adenovirus in urine of healthy and human immunodeficiency virus-infected individuals. J Clin Microbiol 1998; 36 (11): 3323–3326.
19. Echavarria M, Forman M, van Tol MJ, Vossen JM, Charache P, Kroes AC. Prediction of severe disseminated adenovirus infection by serum PCR. Lancet 2001; 358 (9279): 384–385.
20. Schilham MW, Claas EC, van Zaane W, et al. High levels of adenovirus DNA in serum correlate with fatal outcome of adenovirus infection in children after allogeneic stem-cell transplantation. Clin Infect Dis 2002; 35 (5): 526–532.
21. Seidemann K, Heim A, Pfister ED, et al. Monitoring of adenovirus infection in pediatric transplant recipients by quantitative PCR: report of six cases and review of the literature. Am J Transplant 2004; 4 (12): 2102–2108.
22. Teramura T, Naya M, Yoshihara T, Kanoh G, Morimoto A, Imashuku S. Adenoviral infection in hematopoietic stem cell transplantation: early diagnosis with quantitative detection of the viral genome in serum and urine. Bone Marrow Transplant 2004; 33 (1): 87–92.
23. Humar A, Doucette K, Kumar D, et al. Assessment of adenovirus infection in adult lung transplant recipients using molecular surveillance. J Heart Lung Transplant 2006; 25 (12): 1441–1446.